

DISTRICT TWO

OFFICE OF THE MEDICAL EXAMINER

1899 Eider Court • P. O. Box 14389 • Tallahassee, FL 32317 • Phone 850-942-7473 • Fax 850-219-7690

David T. Stewart, M.D., *Medical Examiner*
John P. Mahoney, M.D., *Associate*
Stephen L. Sgan, M.D., *Associate*
Lisa M. Flannagan, M.D., *Associate*
Anthony J. Clark, M.D., *Associate*

CASE NO.
14M-77

DECEASED
FRASCH, Samira

STATE ATTORNEY
William N. Meggs

RACE	SEX	AGE
Black	Female	38

COUNTY DEATH OCCURRED
Leon

DATE OF DEATH
February 22, 2014

INVESTIGATING AGENCY
Leon County Sheriff's Office

DATE & TIME OF AUTOPSY
February 23 2014 at 9:30 a.m.

IN ATTENDANCE
Det. J. Vann, Det. M. Godwin, Det. S. Scott,
Det. J. Weaver and Det. C. Henry

PATHOLOGIST
Lisa M. Flannagan, M.D. 

FINAL PATHOLOGIC DIAGNOSES:

- I. Blunt head trauma.
 - A. Large contusion of right frontal scalp.
 - B. Contusion and abrasion of left temporo-parietal scalp.
 - C. Left side of skull with linear fracture that extends across left basilar skull and midline.
 - D. Cortical contusions of right and left temporal lobes of brain.
 - E. Right subdural hemorrhage (about 20 mL).
- II. Drowning.
 - A. Pulmonary congestion and edema (right lung 830 grams, left lung 740 grams).
 - B. Abundant frothy fluid within the lungs and major bronchi.
- III. Focal mild hemorrhages within strap muscles of neck.
- IV. Mild abrasions of right side of torso and right upper thigh.
- V. Focal abrasions of left lower leg.
- VI. Postmortem blood positive for trimethoprim (trace).

CAUSE OF DEATH: Blunt head trauma and drowning.

EXTERNAL EXAMINATION:

The body is received in a white body bag that has been sealed with a hard red plastic tag bearing "LCSO 140020835". A Tallahassee Memorial HealthCare tag with the decedent's name is attached to the outside of the bag. The body is received lying supine on a pink hospital blanket over a white hospital sheet. Each hand has been secured in a white Tyvek bag. The decedent is nude. No clothing or personal belongings are received with the body.

The body is that of a well-developed and slender female measuring 67 ½ inches, weighing an estimated 120 pounds and appearing to be the reported age of 38 years. The body has not been embalmed and is well-preserved. Rigor mortis is fully developed. Livor mortis is evident over the dorsal aspect of the body. The temperature of the body is cold. Injuries of the head and face will be described below. The head hair is black and long. The hair is damp. The eyes are brown with clear corneas. There are sparse petechiae of the right lower conjunctiva. The right eye shows mild scleral edema with mild hemorrhage along the medial aspect of the eye. The left eye shows pale pink conjunctiva with no petechiae or other focal lesions. The teeth are natural and in good repair. There is a fixed retainer behind the lower teeth. The neck, shoulders and chest are symmetrical. The breasts have palpable implants. There are well-healed scars along the inferior edge of each areola. Minor injuries of the chest and abdomen will be described below. The abdomen is flat. There is a healed piercing just above the umbilicus. The upper pubic area shows a tattoo of "Frasch Love". There is sparse short pubic hair. The back is symmetrical and unremarkable. The external genitalia show no injuries or lesions. A small amount of bloody fluid is present at the anal opening. No lacerations or other injuries of the anus are identified. The left buttock shows a small focal scar. The extremities are symmetrical. The lateral aspect of the left upper arm shows a 2 ½ inch linear scar. The dorsum of the left forearm shows a 2 ¾ inch linear scar. The medial aspect of the left elbow shows a 1 ¼ x ¾ inch scar. There is a smallpox vaccination scar noted on the right lateral shoulder. The anterior right upper arm shows a 1 ¼ inch scar. Gold polish is noted on the fingernails. The nail polish appears to be several days old with chipping of the nail polish distally and nail growth along the proximal aspect of the nail. The fingernails are intact. A small amount of apparent blood is noted on the right middle and ring fingers. The material is swabbed and retained as evidence by law enforcement. Gold glitter polish is present on the toenails. Minor injuries of the extremities will be described below.

EVIDENCE OF MEDICAL INTERVENTION:

A cervical collar is attached around the neck. An endotracheal tube enters the mouth. An intraosseous catheter penetrates the anterior aspect of the left lower leg just below the knee. Electrocardiogram leads are attached to the anterior shoulders. Iatrogenic punctures are noted on the left antecubital fossa, the ventromedial aspect of the proximal left forearm and on the dorsum of the left hand. There is swelling and purple discoloration around the puncture site on the forearm. A Tallahassee Memorial HealthCare band with the decedent's name is attached around the left wrist.

EVIDENCE OF INJURY:**HEAD AND NECK INJURIES:**

- The right side of the forehead and right upper face shows a prominent area of purple swelling. The swelling covers an area that is about 5 x 4 ½ inches. There is extensive hemorrhage in the underlying soft tissues.
- The left temporo-parietal scalp shows a diffuse superficial pink/red abrasion. The scalp in this area is covered with hair. There is subcutaneous hemorrhage in the underlying soft tissues.
- The left side of the skull shows a 1 ½ inch linear fracture of the parietal bone. The fracture extends to the temporal bone and continues anteriorly along the squamosal suture. Along the basilar skull, the fracture continues along the left middle fossa and across the sphenoid bone to cross the midline just anterior to the sella turcica.
- The skull shows slight separation along the lambdoid suture on the posterior aspect of the skull and along the sagittal suture on the superior aspect of the skull.
- There is about 20 ml of subdural hemorrhage over the right cerebral hemisphere. Subarachnoid hemorrhage is present over the right fronto-parietal region of the brain and over the lateral left temporal pole. The infero-lateral aspect of the right temporal lobe is soft and hemorrhagic. The brain is fixed prior to sectioning. Sectioning of the brain reveals small focal cortical hemorrhage of the lateral right and left temporal lobes.
- Focal hemorrhage is present in the left anterior sternocleidomastoid muscle. There is focal sparse hemorrhage in the right sternothyroid muscle.
- Mild hemorrhage is identified in the posterior laryngeal musculature along the right side of the neck.

ADDITIONAL INJURIES:

- The right lower chest shows a 3 x 1 inch area of faint contusions with focal linear scrape abrasions. The injuries are present on the inferior aspect of the right breast and extend downward along the anterolateral aspect of the chest.
- The lateral aspect of the right lower abdomen shows a ½ x ¾ inch dark red dried abrasion.
- The anterolateral aspect of the right proximal thigh shows a 3 ½ x 1 ½ inch area of discontinuous superficial abrasions.
- There is a ¼ inch focal abrasion on the left upper chest.
- The anterior aspect of the left lower leg shows a 3 x ¼ inch linear arrangement of interrupted superficial focal abrasions.
- There is a focal contusion of the left lower leg just lateral to the intraosseous catheter site.

INTERNAL EXAMINATION:**BODY CAVITIES:**

The muscles of the chest and abdominal wall are normal in color and consistency. The organs are in their correct anatomic positions. No abnormal collections of fluid or hemorrhage are present within the body cavities. There are slight postmortem changes of the intestines. The intravascular blood is noted to be liquid and oozes from punctures and incisions.

NECK:

Focal hemorrhages are described above. The hyoid bone, thyroid cartilage and cricoid cartilage are intact. The neck structures are pliable and no fractures are identified. The larynx is patent with no obstructive materials or masses. The laryngeal mucosa is pale and shows no areas of swelling. There is patchy mild submucosal hemorrhage of the inferior larynx and proximal trachea. A mild amount of froth is present in the airway.

CARDIOVASCULAR SYSTEM:

The heart is 300 grams. The epicardial surface is smooth and the heart has a normal configuration. The coronary arteries have the usual take-off and distribution. Sectioning of the coronary arteries reveals no evidence of atheromatous disease. The endocardium is smooth and the valves are unremarkable. The myocardium is tan and homogeneous. No areas of scarring or other focal lesions are identified. The aorta and its major branches are intact.

RESPIRATORY SYSTEM:

The right lung is 830 grams and the left lung is 740 grams. The pleural surfaces are smooth. Abundant white frothy fluid is present within the major bronchi and exudes from the cut surfaces of the lungs. Both lungs are pink/red and soft. No mass lesions or areas of consolidation are identified.

HEPATOBIILIARY SYSTEM:

The liver is 1790 grams. The external surface is smooth. The parenchyma is red/brown and homogeneous. The gallbladder holds about 20 ml of dark green liquid bile and has a smooth mucosal lining. No gallstones are present.

HEMOLYMPHATIC SYSTEM:

The spleen is 150 grams. The capsule is intact. The parenchyma is dark red and has a normal consistency.

GASTROINTESTINAL SYSTEM:

The esophagus has a smooth mucosal lining. The stomach holds about 10 ml of light tan thin mucus. No food or pill fragments are identified. The gastric lining shows no ulcerations or other focal lesions. The intestines are intact with no areas of ischemia or perforation. The rectal mucosa is autolyzed. No trauma or other focal lesions are identified in the anorectal segment of the intestines.

UROGENITAL SYSTEM:

The right kidney is 180 grams and the left kidney is 190 grams. The capsules strip easily to reveal smooth

cortical surfaces. The renal parenchyma is dark red and congested. The corticomedullary junctions are well-defined. The ureters are thin. The bladder holds about 50 ml of clear pale yellow urine and has a smooth mucosal lining. The uterus is the expected size and shape. The endometrial lining is hemorrhagic. The cervix shows bloody mucus at the external os. No injuries of the vaginal wall or cervix are identified. The fallopian tubes are thin. The tubes are noted to be congested and dark red. The left ovary shows surrounding adhesions. The right ovary shows a small hemorrhagic cyst.

ENDOCRINE SYSTEM:

The thyroid gland is the expected size and shape. The parenchyma is dark red with no focal lesions. The adrenal glands show thin cortical ribbons. The pancreas shows early autolysis along the head and body. No focal lesions are identified in the pancreas.

MUSCULOSKELETAL SYSTEM:

Fractures of the skull are described above. No other fractures are identified. No hemorrhage is identified within the musculature of the posterior neck and there are no injuries of the cervical spine.

CENTRAL NERVOUS SYSTEM:

Injuries of the head and brain are described above. The brain is 1400 grams prior to fixation. No underlying pathologic abnormalities of the brain are identified. The posterior aspect of the skull shows a prominent bony protuberance in the area of the lambdoid suture. The frontal bone is moderately thick.

ADDITIONAL PROCEDURES:

1. Toxicologic specimens are collected and submitted for analysis. The specimens include blood from the right iliac vein, urine, bile, vitreous and gastric contents.
2. An air-dried blood spot card is retained.
3. AP & lateral radiographs of the skull are obtained. The films show a possible hairline fracture. On February 27, 2014, I asked Dr. Killius, Radiologist, to review the films to assess bone density. He states that there appears to be no abnormalities with the bone density.
4. The following evidence is collected in conjunction with Det. Vann and is retained in his custody: Tyvek bags from the hands, nail scrapings and clippings from both hands, swabs of right hand (control, right middle and right ring fingers), fingerprints, a purple-top tube of blood, sexual assault kit (pulled head hairs, pulled pubic hairs, combed pubic hairs, anal swabs, oral swabs, buccal swabs, and vaginal swabs), and pink hospital blanket from under body.

MICROSCOPIC EXAMINATION:

HEART: (C)
abnormalities.

No specific pathologic

LUNGS: (D, E)
abnormalities.

No specific pathologic

AUTOPSY REPORT

FRASCH, Samira
14M-77

LIVER: (B)
abnormalities.

No specific pathologic

PANCREAS: (B)

Acute interstitial hemorrhage.

KIDNEY: (A)
glomeruli with associated tubular dropout and chronic inflammation.

Focal area of sclerotic

SPLEEN: (A)
abnormalities.

No specific pathologic

STERNOCLEIDOMASTOID MUSCLE: (F)
associated inflammatory cell infiltrate.

Acute hemorrhage with no

BONE MARROW: (N)
and myeloid precursors with maturation. Megakaryocytes are present.

Normal cellularity. Erythroid

PONS: (G)
abnormalities.

No specific pathologic

CEREBELLUM: (H)
abnormalities.

No specific pathologic

RIGHT TEMPORAL LOBE: (I, J, K)
along the crests of gyri. Acute leptomeningeal hemorrhage. Small perivascular white matter hemorrhages.


Acute cortical hemorrhages

LEFT TEMPORAL LOBE: (L)
Acute leptomeningeal hemorrhage.

Acute subpial hemorrhages.

HIPPOCAMPUS: (M)
hemorrhage.

Acute leptomeningeal


Lisa M. Flannagan, M.D.
Associate Medical Examiner

LMF/lcb/trp
Completed: March 14, 2014

- CONFIDENTIAL -

University of Florida Pathology Laboratories
Department of Pathology and Laboratory Medicine
4800 SW 35th Drive
Gainesville, FL 32608
Phone: 352-265-9900 Fax: 352-265-9904

Page: 1 of 1

LAB NUMBER: R14-00390
NAME: Frasch, Samira
CASE NO: 14M-077
RECEIPT DATE: 02/25/2014

Forensic Toxicology Laboratory


SUBMITTER: Dr. Lisa Flannagan, District 2 Medical Examiners Office, 1899 Eider Court, Tallahassee, FL 32308.**SPECIMENS RECEIVED:**

- A. Blood, right iliac vein
- B. Urine
- C. Bile
- D. Vitreous Humor
- E. Stomach Contents

	<u>Analyte</u>	<u>Qualitative Results</u>	<u>Quantitative Results</u>
VOLATILES			
A. Blood	None Detected		
B. Urine	None Detected		
COMPREHENSIVE DRUG SCREEN			
A. Blood	Trimethoprim	Positive (trace)	
B. Urine	Trimethoprim	Positive	

RESULT CERTIFICATION:

Results Certified by:

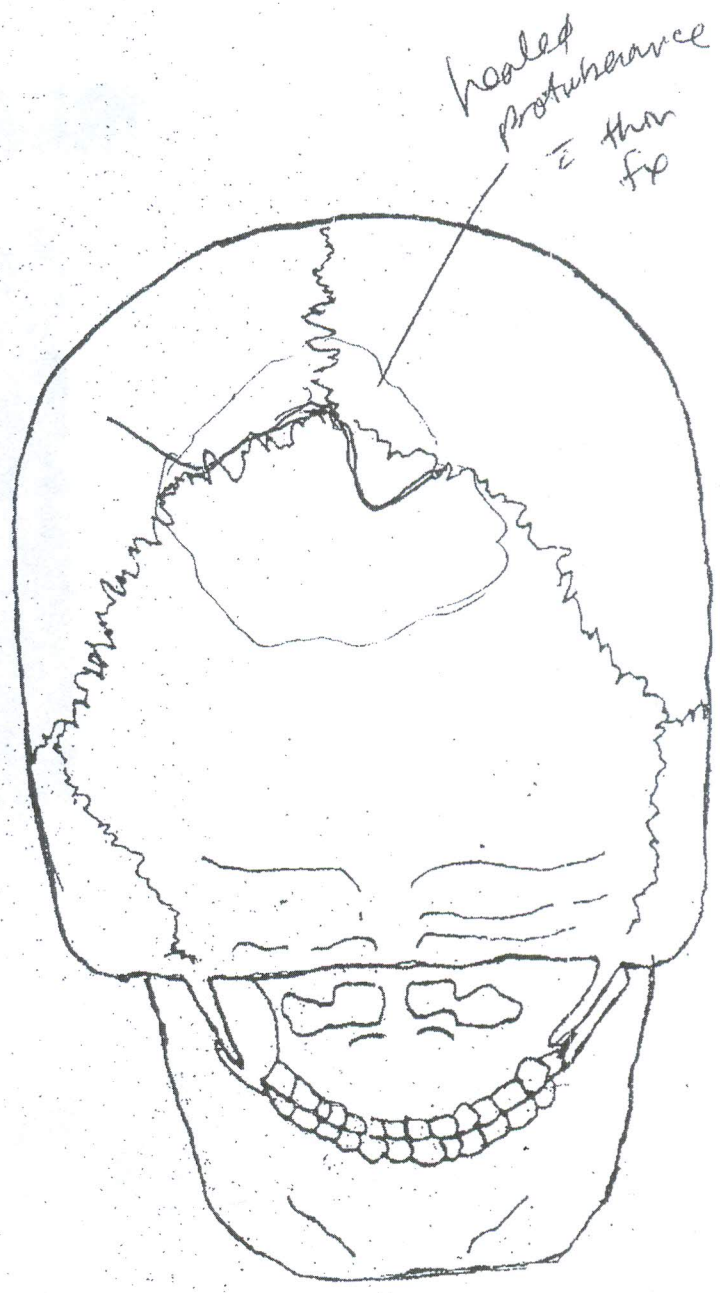
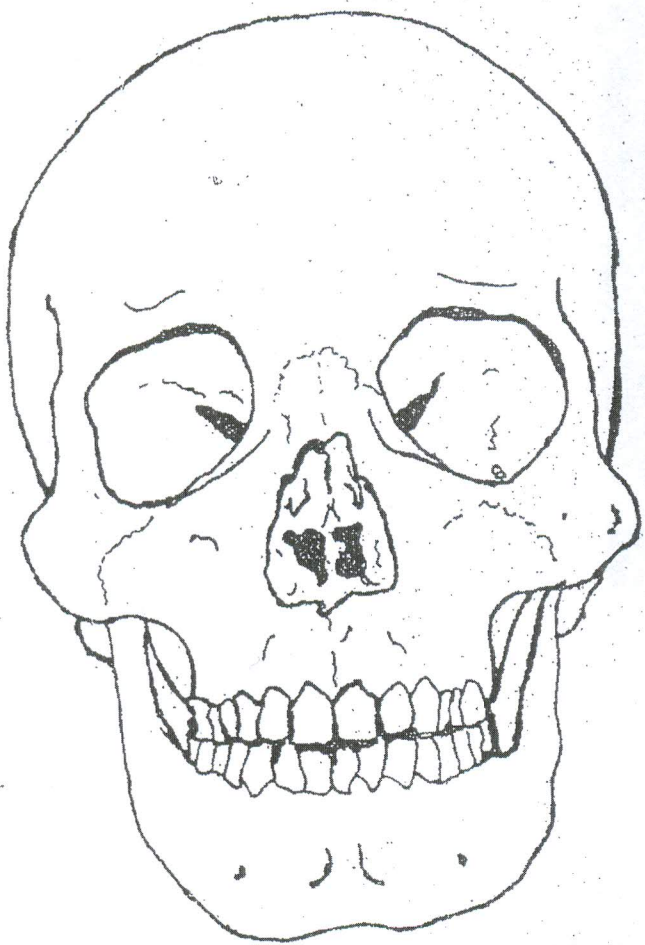

Bruce A. Goldberger, Ph.D., DABFT
Director of Toxicology & Professor

R1400390 - 01/ BG
PRINTED: 03/11/14

03/11/14 [0001]

Name — FRASCH,
SAMIRA
Age — 38 YRS B F 2/23/2014 14M-77
LEON LMF

Autopsy) _____ 14m-77
Date | | _____

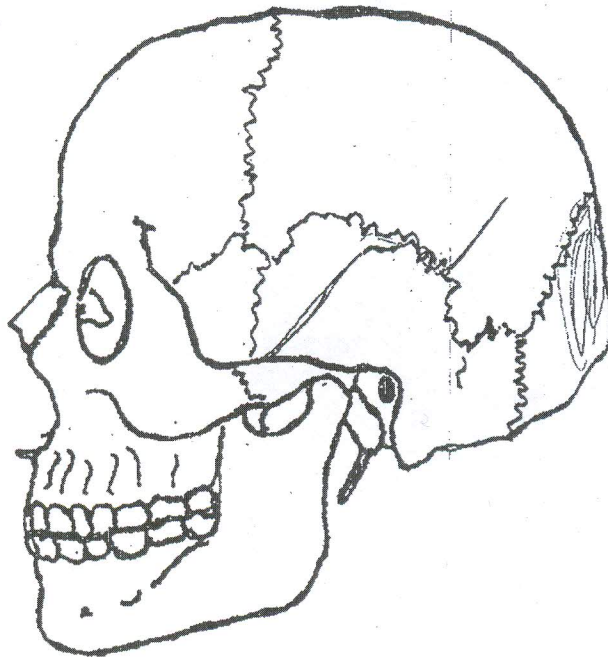
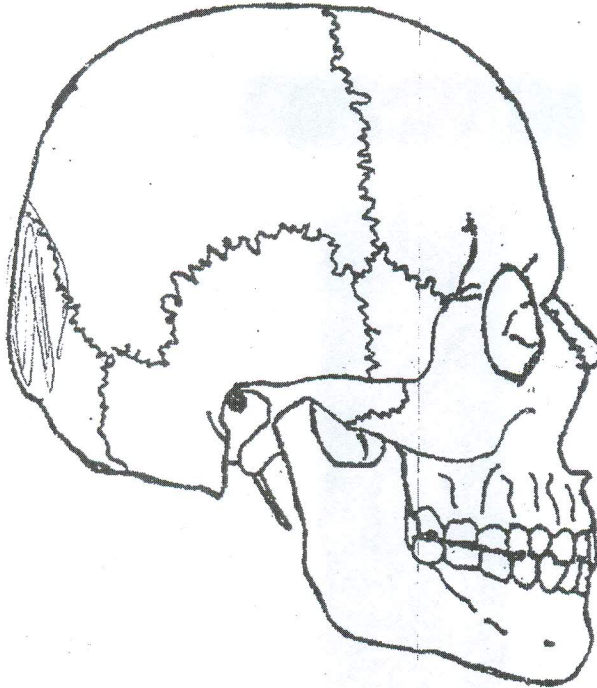


S. Slattery MD

Name FRASCH, SAMIRA
Age 38 YRS B F 2/23/2014 14M-77
LEON LMF

Autopsy No. 14M-77
Date 1 1

thin
fx
post over
healed
deformity



healed bony
protuberance
thin fx along
① side of skull
1 1/2" along parietal bone

Blannay MA

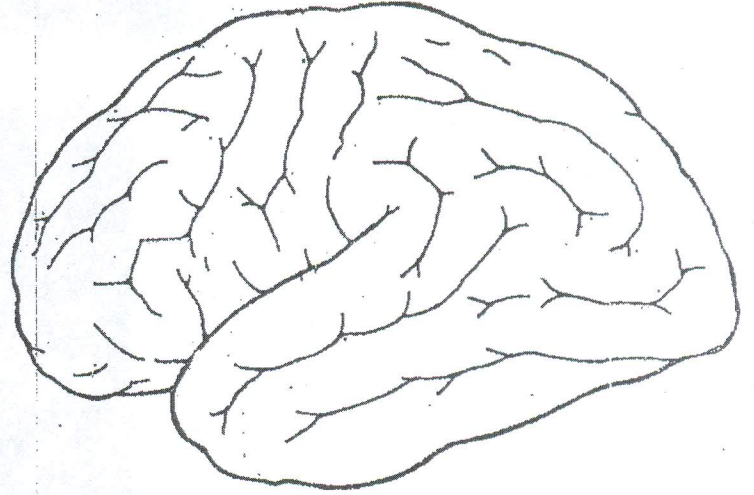
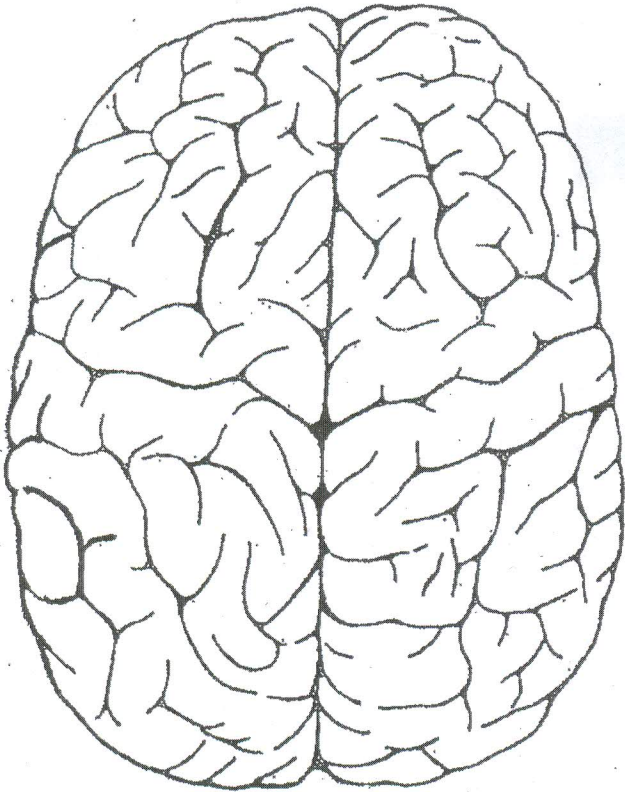


FRASCH,
Nan SAMIRA
38 YRS B F 2/23/2014 14M-77
Age LEON LMF

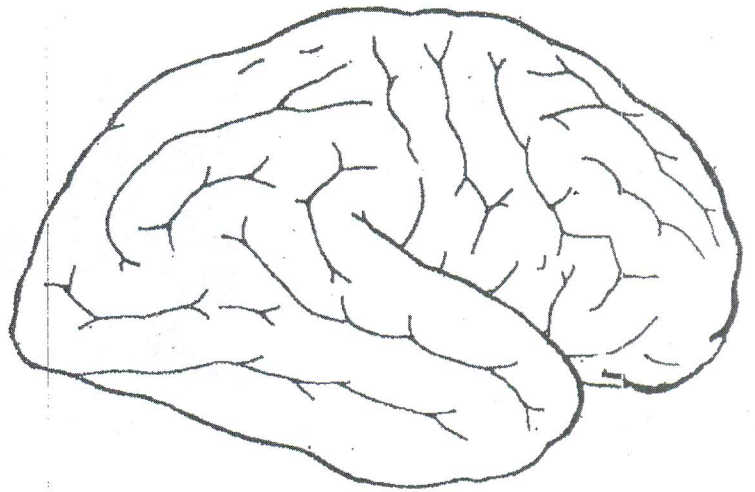
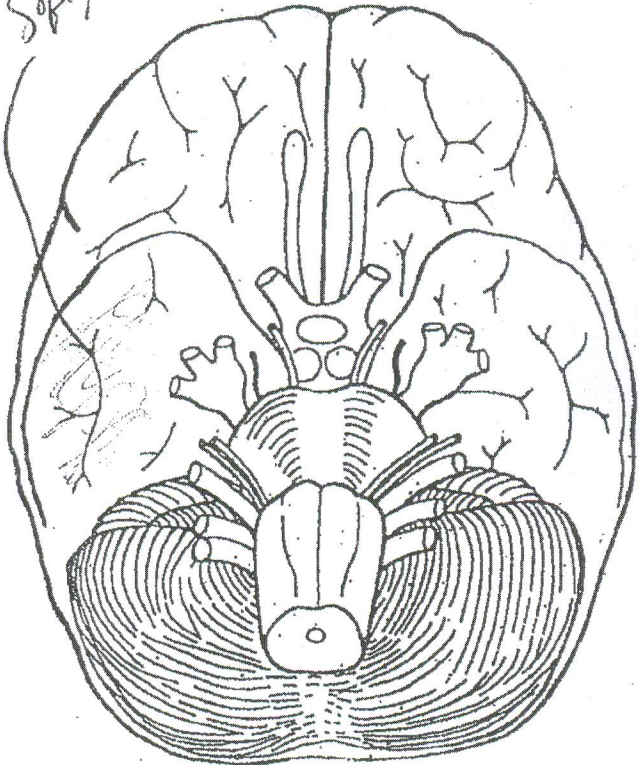
Psy No. 14m-77

Date / /

brain fixed



Soft, hemorrhagic



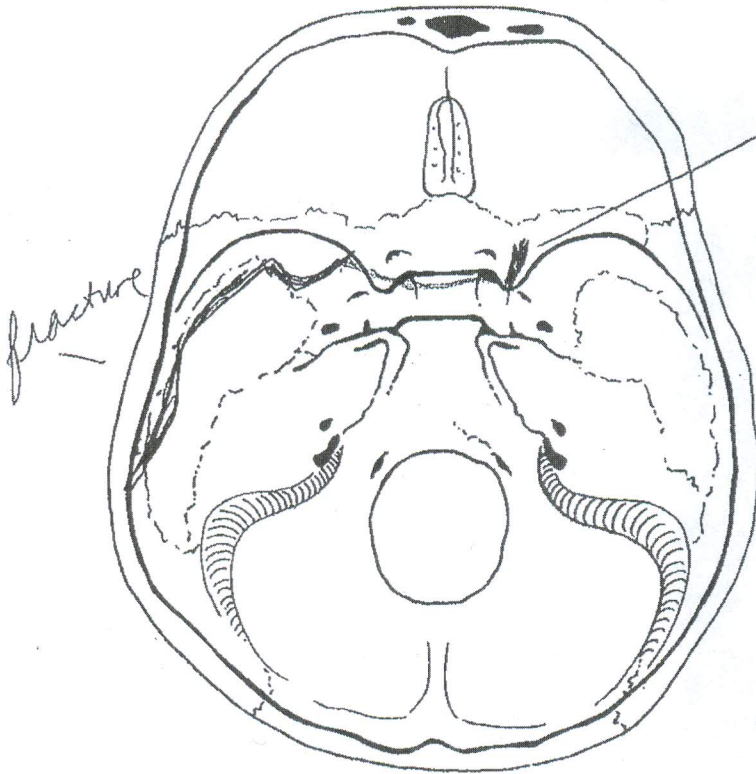
Cat. No. 44-1-019-00

Stemazema



Skull, base
 Name FRASCH, SAMIRA
 38 YRS B F 2/23/2014 14M-77
 Age LEON LMF

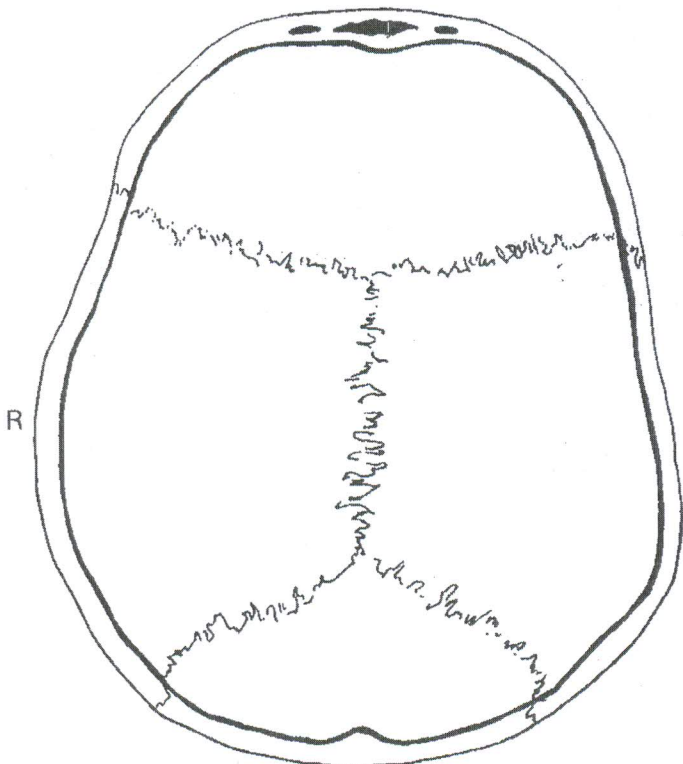
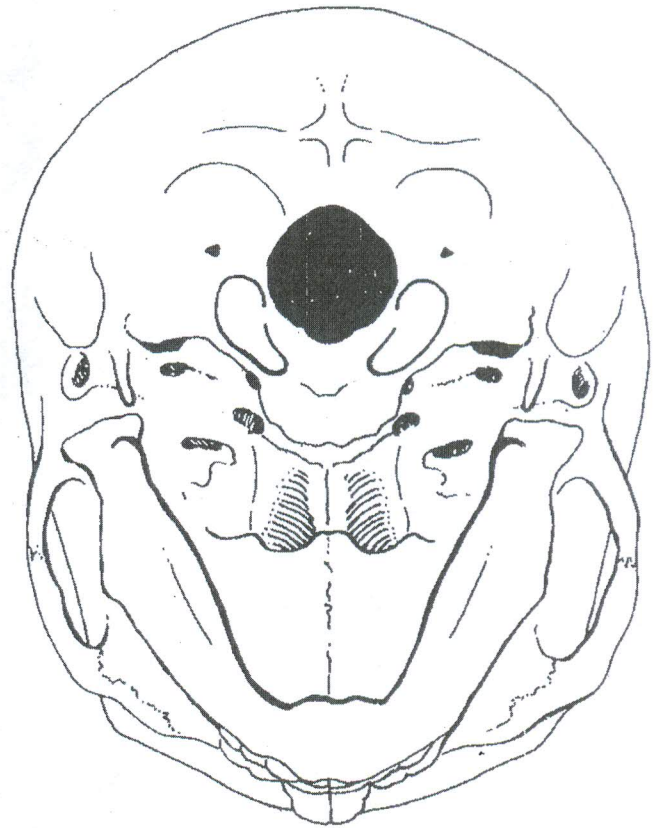
is calvarium:)
 Autopsy No. 14M-77
 Date / /



fracture

fracture

hem. along petrous
 portions of temporal
 bones



R

L

INNER VIEW OF SKULL

Case No. 44-1017-22

SDH (20 ml)
 over @ hemisphere
 contusions of @ side of
 brain - soft,
 (temporal) hemorrhagic

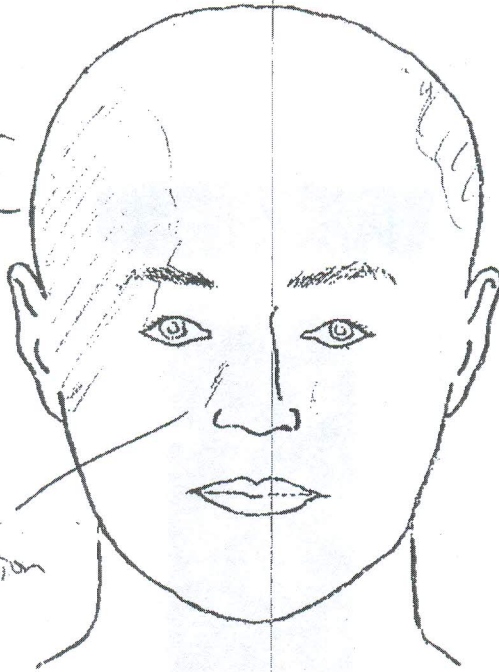
fracture

BODY DIAGRAM—HEAD

14M-77

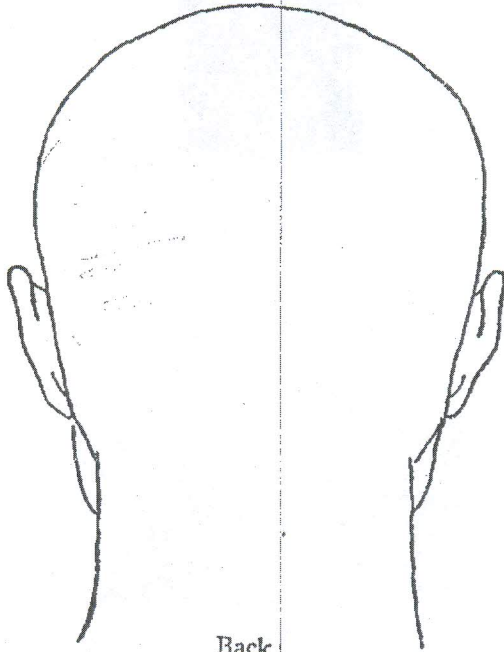
Purple Swollen
~5 x 4 1/2"
↑ Subcutaneous
hem

Faint
abrasion



Front

Subcut.
hem
⊙ lat/parietal



Back

Decedent's Name Samira Frasch

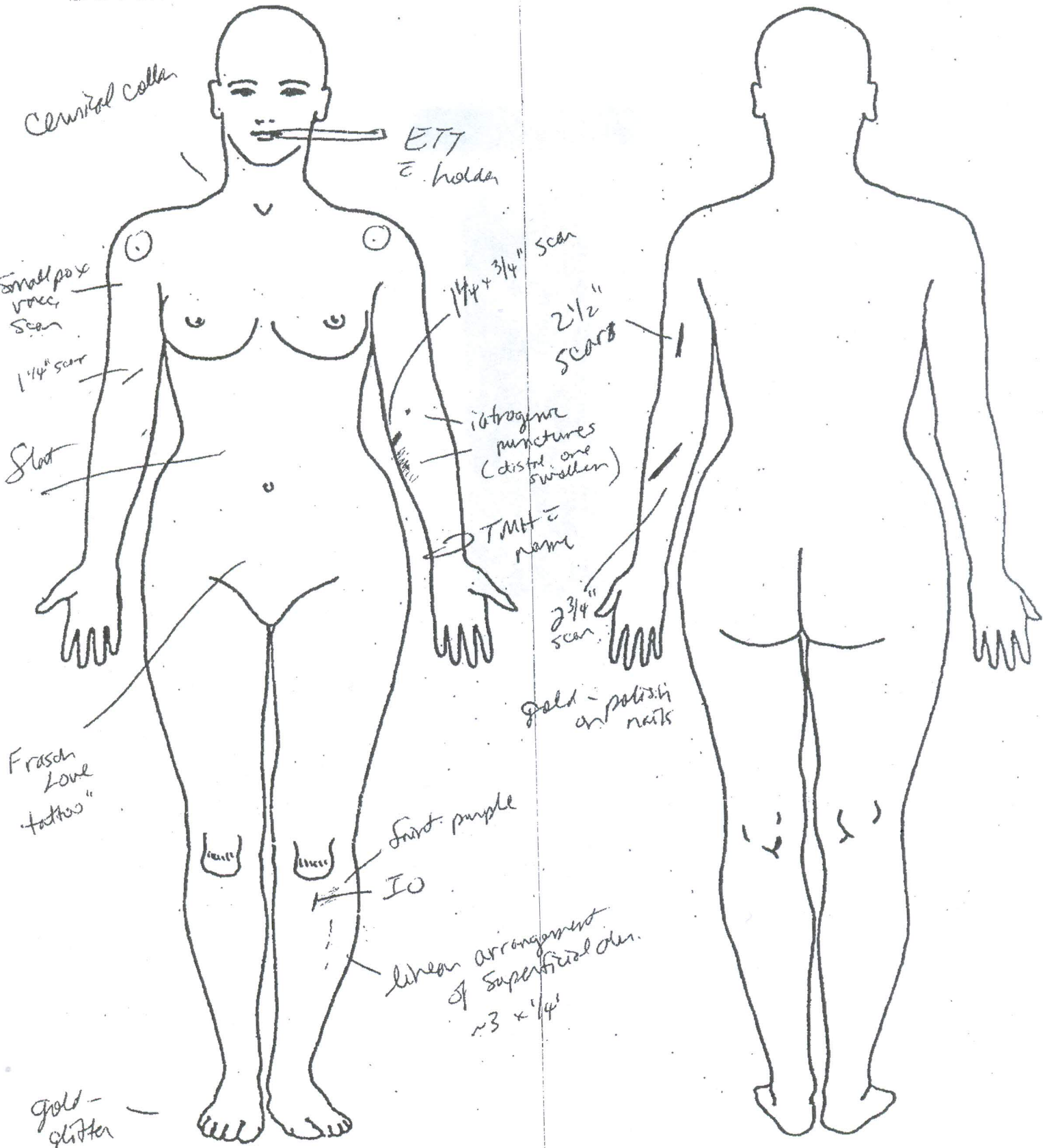
Examined By Blaney MD Date 2/23/14

FRASCH,
SAMIRA
38 YRS B F 2/23/2014 14M-77
LEON LMF

Anterior and posterior views.

Autopsy No. 14M-77

Sex _____ Date 1 / 1



S. Slennayms

Full body, female, anterior and posterior views.

Name _____ FRASC.,
SAMIRA
Age _____ 38 YRS B F 2/23/2014 14M-77
LEON LMF

Psy No. 14M-77
Date / /

Multip
Swollen

1/4" abn

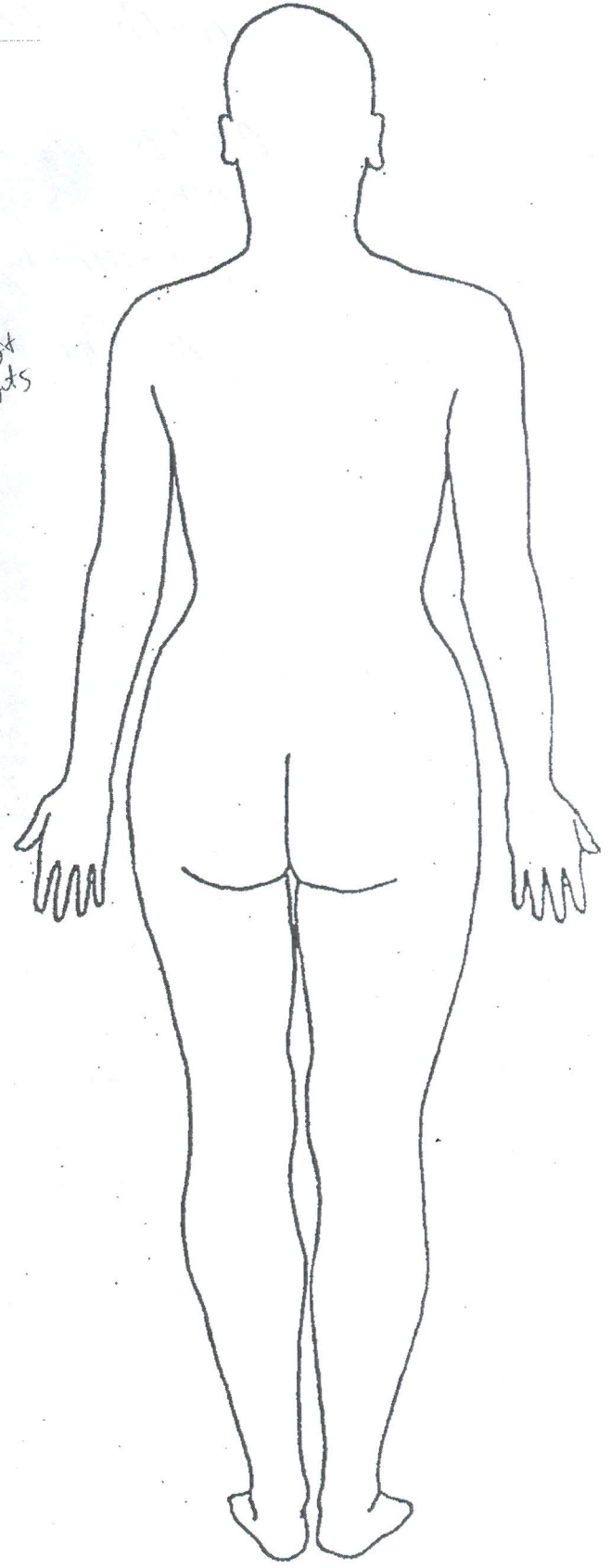
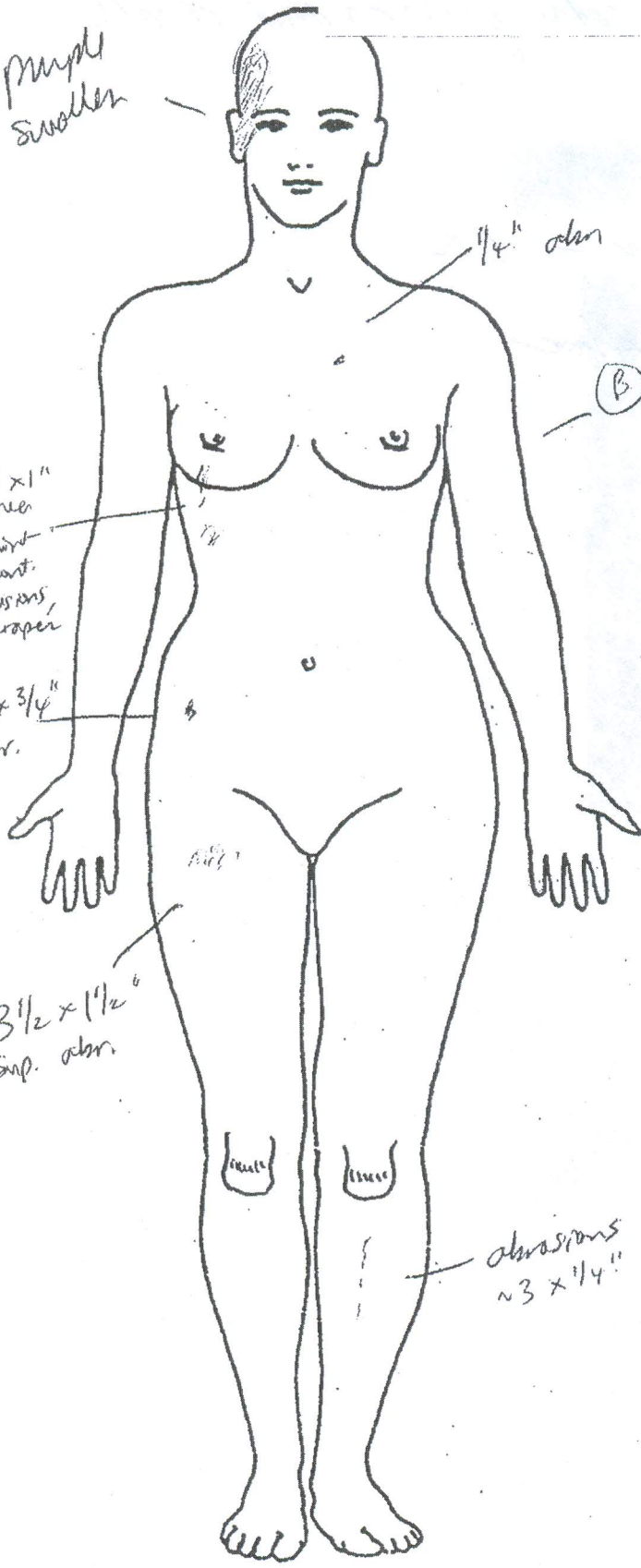
(B) breast
implants

~3 x 1"
scr. abras
faint
abrasions
scrapes

1/2 x 3/4"
abr.

3 1/2 x 1 1/2"
sup. abn.

abrasions
~3 x 1/4"



Stennay MD